

Bicuspid Aortic Valve

Nuran Yener, PhD,¹ G. Levent Oktar, MD,² Dilek Erer, MD,³ M. Murat Yardimci, MD,³ and Ali Yener, MD³

The bicuspid aortic valve is a common congenital cardiac anomaly, having an incidence in the general population of 0.9% to 2.0% and a frequency of 54% in all patients aged >15 years with valvular aortic stenosis. In most cases it remains undetected until infective endocarditis or calcification supervenes. The bicuspid aortic valve may function normally throughout life, may develop progressive calcification and stenosis or may develop regurgitation with or without infection. The association of the bicuspid aortic valve with dissection of the aorta is also common. The recognition of the bicuspid valve in patients with aortic valve disease remains an important challenge to the clinician, whereas preoperative knowledge of valve morphology would be helpful in planning the surgery. Antibiotic prophylaxis is also recommended in such patients, since these valves are likely to become the most important intrinsic cardiac predisposition for infective endocarditis with the virtual disappearance of rheumatic fever in developed countries. (Ann Thorac Cardiovasc Surg 2002; 8: 264–7)

Key words: bicuspid aortic valve, aortic stenosis, aortic regurgitation, infective endocarditis, aortic dissection

Introduction

The bicuspid aortic valve is a common congenital cardiac anomaly, having an incidence in the general population of 0.9 to 2.0% and a frequency of 54% of all patients aged >15 years with valvular aortic stenosis.¹ It was first described as a pathological curiosity in 1844 by Paget; Peacock recognized its liability to calcific stenosis in 1866; and in 1886, Osler first associated it with infective endocarditis.² The association of bicuspid aortic valve with aortic stenosis, aortic regurgitation, dissection of the aorta and infective endocarditis causes this anomaly to be an important challenge to the clinician.

From ¹Department of Anatomy, Hacettepe University, Faculty of Medicine, ²Division of Cardiovascular Surgery, Dr. M. Ülker Emergency and Traumatology Hospital, ³Department of Thoracic and Cardiovascular Surgery, Gazi University, Faculty of Medicine, Ankara, Turkey

Received January 16, 2002; accepted for publication January 28, 2002.

Reprint requests to G. Levent Oktar, MD: Kizilirmak Mah. 8. Sokak, Halkbank Sitesi C Block No. 7/23, 06520 Balgat, Ankara, Turkey.

Morphology

The leaflets of a bicuspid aortic valve are usually of unequal size with a raphe or false commissure apparent in the larger of the leaflets (Fig. 1).³ Histological examination shows no valve tissue in the raphe.⁴ The leaflets are usually oriented right and left with the true commissures oriented anterior and posterior, but may also be in an anteroposterior orientation. Most commonly, the right and left coronary leaflets comprise the larger, fused leaflet and the noncoronary leaflet is separate with true commissures. The free edges of a bicuspid valve are more straight than rounded producing limited mobility.³ The coronary arteries usually arise in front of the cusp with a raphe.⁵ Stenosis usually develops in bicuspid valves containing no redundant cusp tissue, and incompetence often in valves in which redundancy and prolapse are prominent.^{6,7} Calcification increases with age and is largely confined to the raphe and base of the cusp, as it is in degenerative valves.⁸

Bicuspid aortic valves have been reported in 20-85% of cases of coarctation of the aorta and in 27% of cases of

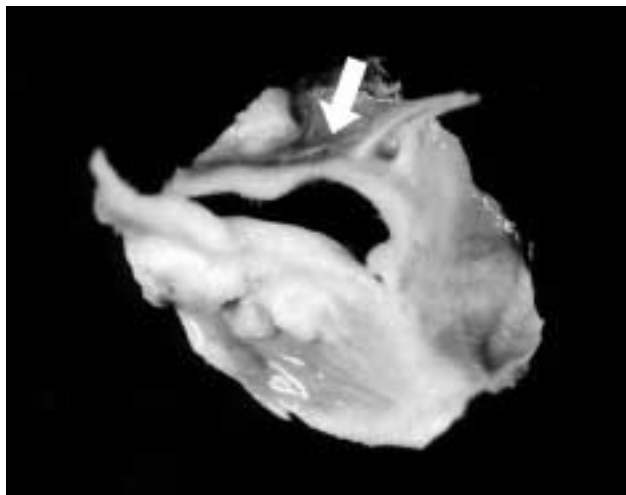


Fig. 1. The bicuspid aortic valve of a 40-year-old male patient who underwent aortic valve replacement with a 23-mm St. Jude mechanical prosthesis for combined aortic stenosis and regurgitation with a gradient of 80 mmHg. Arrow shows the raphe or false commissure.

interrupted aortic arch.⁹⁻¹¹⁾

Left coronary artery dominance is more common in patients with a bicuspid aortic valve (29-56.8%) and in 90% of cases, the left main coronary artery is less than 5 mm in length.^{12,13)} The ignorance of these associations may cause an inadequate myocardial preservation and an increased risk of myocardial infarction.¹⁰⁾

Genetics

The genetics of bicuspid aortic valves have been studied by several investigators.¹⁴⁾ These valves may run in families in a multifactorial inheritance pattern or occasionally in an autosomal dominant one. Emanuel et al. have found a minimum family incidence of 14.6% of bicuspid aortic valves.¹⁵⁾ In a recent study of first degree relatives of individuals with bicuspid aortic valves, the prevalence of this defect was found to be 9.1%, which was well above the estimated population prevalence of 1-2%.¹⁶⁾ Although these valves are more common in males than females by a factor of 2:1 in the general population, the prevalence was equal in males and females in families having more than one affected individual.^{15,17)}

Diagnosis

The recognition of the bicuspid aortic valve in patients with aortic valve disease remains an important challenge to the clinician.¹⁸⁾ The reliability of the diagnosis has been significantly improved by the introduction of cross sectional and Doppler echocardiography.¹⁹⁾ Diagnosis is

based on the demonstration of two cusps and two commissures during short axis visualisation. Supportive features include cusp redundancy and eccentric valve closure, and a single coaptation line between the cusps during diastole.⁸⁾ Although in patients with adequate transthoracic echocardiograms, a sensitivity and specificity of 78 and 96%, respectively, for the identification of a bicuspid aortic valve have been reported, in up to 25% of patients, morphology of the aortic valve cannot be determined by transthoracic echocardiography.^{18,20)} In a recent study, Espinal and colleagues have reported their experience with transesophageal echocardiography shows a high degree of sensitivity and specificity for determining aortic valve morphology, especially when using the multi-plane approach.¹⁸⁾

Natural History and Complications

The congenitally bicuspid valve may function normally throughout life, may develop progressive calcification and stenosis or may develop regurgitation with or without infection.¹⁾ The natural history of this valve is of calcification and is the most common cause of isolated aortic stenosis.^{21,22)} The congenital variety of aortic stenosis is the most common, and accounts for two-thirds of the nonrheumatic patients.¹⁾ Severely stenosed bicuspid aortic valves are very rigid because of fibrosis and heavy calcification, but are not narrowed.^{4,22)} Both calcification and fibrosis are age related.²³⁾ Most patients with a bicuspid aortic valve have abnormal valvular calcification by the age of 20, and nearly all show calcification by 30 years

of age.²⁴⁾ Stenosis progresses more rapidly (27 mmHg per decade) if the cusps are asymmetrical in size and in the anteroposterior location.²⁵⁾ Patients with aortic stenosis secondary to a bicuspid aortic valve were found to require aortic valve replacement five years before those with a tricuspid valve.²⁶⁾

The incidence of aortic regurgitation secondary to bicuspid aortic valves was reported to be 1.5 to 3%.^{5,27)} It may occur in isolation, usually as a result of prolapse of the larger of the cusps, but also in association with aortic root dilatation, coarctation of the aorta, or infective endocarditis.²⁸⁻³⁰⁾ Pachulski et al. found that the aortic root diameter was significantly larger among patients with bicuspid aortic valves than among normal controls, even in the absence of hemodynamically significant aortic stenosis.³¹⁾ Disruption or dissolution of elastic tissue within the upper aortic ring causes root dilatation and aortic regurgitation.²⁹⁾ Infective endocarditis is responsible for between 43 and 60% of cases of severe aortic regurgitation in patients with a bicuspid aortic valve, the result of cusp perforation in the majority of the cases.^{7,28)}

Infective endocarditis is a well-recognized complication of a bicuspid aortic valve; autopsy evidence suggests that it occurs in 7-25% of cases and usually presents in the fourth and fifth decade of life, requiring major surgery in most cases, with significant mortality (9%).³⁰⁾ Bicuspid aortic valve endocarditis predominantly occurs in young adults and there is a strong male dominance (73-100%). The mean age in the adult series varies between 38 and 53 years.^{30,32)} Staphylococci and viridans streptococci have accounted for nearly three-quarters of the cases, as in native valve endocarditis. Complications, especially heart failure and valvular or myocardial abscesses are common. Most patients require surgery, often on an emergency basis.³⁰⁾ Recent surgical series show that 25 to 54% of all infected aortic valves are bicuspid.³²⁻³⁴⁾ Bicuspid aortic valves are likely to become the most important intrinsic cardiac predisposition for infective endocarditis with the virtual disappearance of rheumatic fever in the developed countries.³⁰⁾

A bicuspid aortic valve is present in 7 to 13% of unselected cases of aortic dissection.^{35,36)} The risk of dissection in patients with bicuspid aortic valves is reported to be nine times higher.³⁷⁾ Aortic dissection usually occurs in the presence of a normally functioning valve, but it may also occur with stenosed bicuspid aortic valves and following aortic valve replacement, at a site remote from surgical access to the valve.³⁵⁻³⁸⁾ Abnormalities in the ascending aorta of the patients with bicuspid aortic

valves, specifically premature medial layer smooth muscle cell apoptosis, have been described, explaining the higher-than-expected prevalence of aortic dissection in these patients.³⁹⁾ Also morphometric studies show less elastic tissue in the aortas of bicuspid aortic valve patients.⁴⁰⁾ These findings may one day make it advisable to consider replacement of the ascending aorta when valve replacement is performed in the patient with a bicuspid aortic valve.¹⁸⁾

Conclusion

Congenital bicuspid aortic valves are common and in most cases remain undetected until infection or calcification supervenes.³⁰⁾ Aortic stenosis and regurgitation, infective endocarditis and aortic dissection are the most common complications. The recognition of the bicuspid valve in patients with aortic valve disease remains an important challenge to the clinician, whereas preoperative knowledge of valve morphology would be helpful in planning the surgery. Echocardiography should be undertaken in all young adults in whom murmurs are detected and possibly also in the first- and second-degree relatives of patients with known bicuspid aortic valves.³⁰⁾ Antibiotic prophylaxis for infective endocarditis is also recommended in such patients.

References

1. Hammond GL, Letsou GV. Aortic valve disease and hypertrophic cardiomyopathies. In: Baue AE ed.; Glenn's Thoracic and Cardiovascular Surgery. Connecticut: Appleton & Lange, 6th ed. 1996; pp 1981–2003.
2. Osler W. The bicuspid condition of the aortic valves. *Transactions of the Association of American Physicians* 1886; **1**: 185–92.
3. Clarke DR, Bishop DA. Congenital malformations of the aortic valve and left ventricular outflow tract. In: Baue AE ed.; Glenn's Thoracic and Cardiovascular Surgery. Connecticut: Appleton & Lange, 6th ed. 1996; pp 1221–42.
4. Pomerance A. Pathogenesis of aortic stenosis and its relation to age. *Br Heart J* 1972; **34**: 569–74.
5. Roberts WC. The congenitally bicuspid aortic valve. *Am J Cardiol* 1970; **26**: 72–83.
6. Peacock TB. Valvular Disease of the Heart. London: Churchill, 1865; pp 2–33.
7. Olson LJ, Subramanian R, Edwards WD. Surgical pathology of pure aortic insufficiency: a study of 225 cases. *Mayo Clin Proc* 1984; **59**: 835–41.
8. Ward C. Clinical significance of the bicuspid aortic valve. *Heart* 2000; **83**: 81–5.

9. Stewart AB, Ahmet R, Travill CM, et al. Coarctation of the aorta, life and health 20-44 years after surgical repair. *Br Heart J* 1993; **69**: 65-70.
10. Presbitero P, Demarie D, Villani M, et al. Long term results (15-30 years) of surgical repair of aortic coarctation. *Br Heart J* 1987; **57**: 462-7.
11. Roberts WC, Morrow AG, Braunwald E. Complete interruption of the aortic arch. *Circulation* 1962; **26**: 39-59.
12. Hutchins GM, Nazarian IH, Bulkley BH. Association of left dominant coronary arterial system with congenital bicuspid aortic valve. *Am J Cardiol* 1978; **42**: 57-9.
13. Higgins CB, Wexler L. Reversal of dominance of the coronary arterial system in isolated aortic stenosis and bicuspid aortic valve. *Circulation* 1975; **52**: 292-6.
14. Gelb BD, Zhang J, Sommer RJ, Wasserman JM, Reitman MJ, Willner JP. Familial patent ductus arteriosus and bicuspid aortic valve with hand anomalies: a novel heart-hand syndrome. *Am J Med Genet* 1999; **87**: 175-9.
15. Emanuel R, Withers R, O'Brien K, Ross P, Feizi O. Congenitally bicuspid aortic valves: clinicogenetic study of 41 families. *Br Heart J* 1978; **40**: 1402-7.
16. Huntington K, Hunter AG, Chan KL. A prospective study to assess the frequency of familial clustering of congenital bicuspid aortic valve. *J Am Coll Cardiol* 1997; **30**: 1809-12.
17. Clementi M, Notari L, Borghi A, Tenconi R. Familial congenital bicuspid aortic valve: a disorder of uncertain inheritance. *Am J Med Genet* 1996; **62**: 336-8.
18. Espinal M, Fuisz AR, Nanda NC, Aaluri SR, Mukhtar O, Sekar P. Sensitivity and specificity of transesophageal echocardiography for determination of aortic valve morphology. *Am Heart J* 2000; **139**: 1071-6.
19. Weyman AE, Griffin BP. Left ventricular outflow tract: the aortic valve, aorta and subvalvular outflow tract. In: Weyman AE ed.; *Principles and Practice of Echocardiography*, 2nd ed. Philadelphia: Lea and Febiger, 1994; pp 505-8.
20. Brandenburg RO Jr, Tajik AJ, Edwards WD, et al. Accuracy of 2-dimensional echocardiographic diagnosis of congenitally bicuspid valve: echocardiographic-anatomic correlation in 115 patients. *Am J Cardiol* 1973; **83**: 1469-73.
21. Bacon APC, Matthews MB. Congenital bicuspid aortic valves and the aetiology of isolated aortic valvular stenosis. *Q J Med* 1959; **112**: 545-60.
22. Fenoglio JJ, McAllister HA Jr, DeCastro CM, Davia JE, Cheitlin MD. Congenital bicuspid aortic valve after age 20. *Am J Cardiol* 1977; **39**: 164-9.
23. Subramanian R, Olson LJ, Edwards WD. Surgical pathology of pure aortic stenosis: a study of 374 cases. *Mayo Clin Proc* 1984; **59**: 683-90.
24. Jacobs ML, Austen WG. Acquired aortic valve disease. In: Sabiston DC, Spencer FC eds.; *Surgery of the Chest*. Philadelphia: W.B. Saunders Co., 1990; pp 1566-96.
25. Beppu S, Suzuki S, Matsuda H, et al. Rapidity of progression of aortic stenosis in patients with congenital bicuspid aortic valve. *Am J Cardiol* 1993; **71**: 322-7.
26. Mautner GC, Mautner SL, Cannon RD, et al. Clinical factors useful in predicting aortic valve structure in patients >40 years of age with isolated valvular aortic stenosis. *Am J Cardiol* 1993; **72**: 194-8.
27. Grant RT, Wood JE, Jones TD. Heart valve irregularities in relation to sub-acute bacterial endocarditis. *Heart* 1928; **14**: 247-55.
28. Roberts WC, Morrow AG, McIntosh CL, et al. Congenitally bicuspid aortic valve causing severe pure aortic regurgitation without superimposed infective endocarditis. *Am J Cardiol* 1981; **47**: 206-9.
29. Guiney TE, Davies MJ, Parker DJ, et al. The aetiology and course of isolated severe aortic regurgitation. *Ann Intern Med* 1987; **58**: 358-68.
30. Lamas CC, Eykyn SJ. Bicuspid aortic valve—A silent danger: analysis of 50 cases of infective endocarditis. *Clin Infect Dis* 2000; **30**: 336-41.
31. Pachulski RT, Weinberg AL, Chan KL. Aortic aneurysm in patients with functionally normal or minimally stenotic bicuspid aortic valve. *Am J Cardiol* 1991; **67**: 781-2.
32. Janatuinen MJ, Vanttinen EA, Nikoskelainen J, Inberg MV. Surgical treatment of active native endocarditis. *Scand J Thorac Cardiovasc Surg* 1990; **24**: 181-5.
33. Varstela E, Verkkala K, Pohjola-Sintonen S, Valtonen V, Maamies T. Surgical treatment of infective aortic valve endocarditis. *Scand J Thorac Cardiovasc Surg* 1991; **25**: 167-74.
34. Michel PL, Aubert I, Boustani F, Acar J. Chirurgie de l'insuffisance aortique bacterienne. Indications et resultats. *Ann Med Interne (Paris)* 1987; **138**: 610-4.
35. Roberts CS, Roberts WC. Dissection of the aorta associated with congenital malformation of the aortic valve. *J Am Coll Cardiol* 1991; **17**: 712-6.
36. Edwards WD, Leaf DS, Edwards JE. Dissecting aortic aneurysm associated with congenital bicuspid aortic valve. *Circulation* 1978; **57**: 1022-5.
37. Larson EW, Edwards WD. Risk factors for aortic dissection: a necropsy study of 161 cases. *Am J Cardiol* 1984; **53**: 849-55.
38. Fukuda T, Tadavarthy SM, Edwards JE. Dissecting aneurysm of aorta complicating aortic valvular stenosis. *Circulation* 1976; **53**: 169-75.
39. Bonderman D, Gharehbaghi-Schnell E, Wollenek G, et al. Mechanisms underlying aortic dilatation in congenital aortic valve malformation. *Circulation* 1999; **99**: 2138-43.
40. Parai JL, Masters RG, Walley VM, Stinson WA, Veinot JP. Aortic medial changes associated with bicuspid aortic valve: myth or reality? *Can J Cardiol* 1999; **15**: 1233-8.